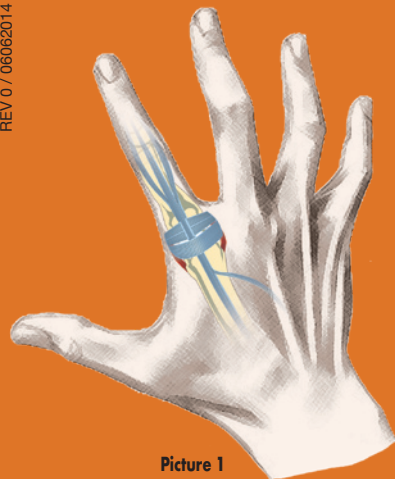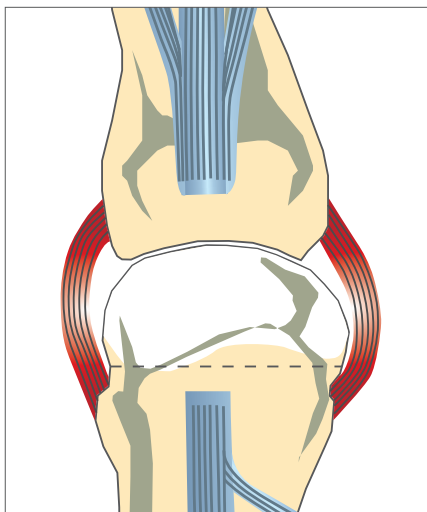


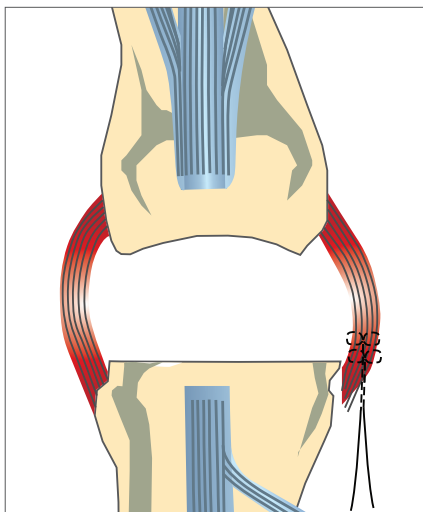
Picture 1

# RegJoint™

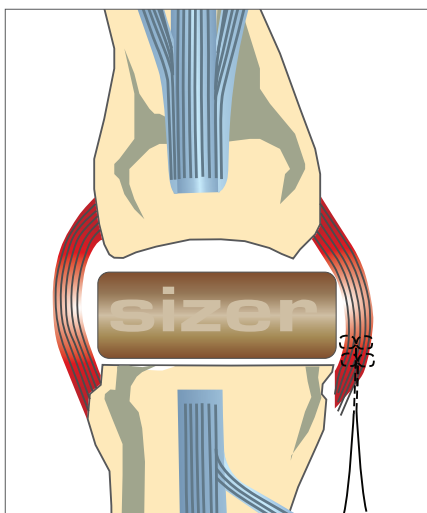
## surgical technique



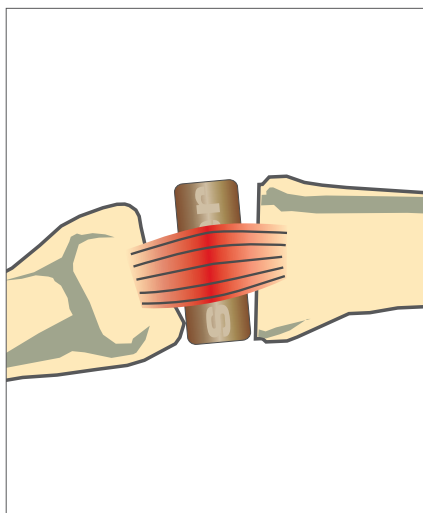
Picture 2



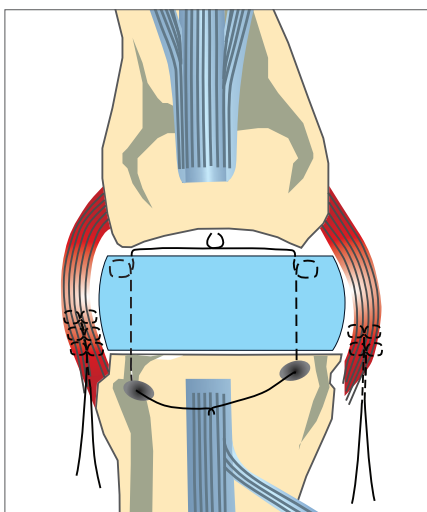
Picture 3



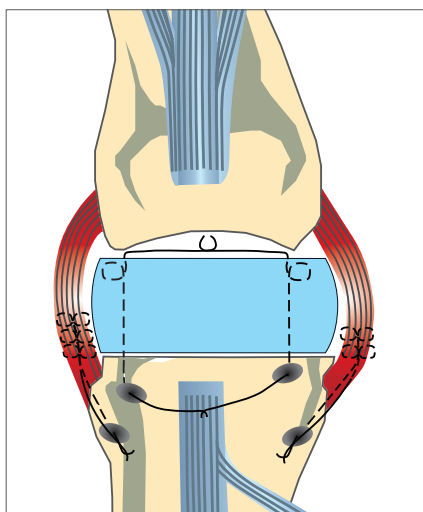
Picture 4 A



Picture 4 B



Picture 5



Picture 6

## Metacarpophalangeal (MCP II-V) joints

### Picture 1:

Opening of the extensor hood longitudinally on the radial or ulnar side of the extensor tendon. In case of subluxated tendon the ulnar sagittal band and transverse fibres are divided to mobilise the tendon in a radial direction.

### Picture 2:

The metacarpal head is resected just distal to the collateral insertions.

### Picture 3:

The ulnar collateral ligament is released from the metacarpal origin and picked up by the absorbable holding core suture. The palmar joint capsule is detached from the metacarpal and the palmar plate can be released by a longitudinal incision to correct the palmar subluxation.

### Picture 4 A:

RegJoint™ size can be used to evaluate the correct size of the implant. Ideal size completely covers the bone end.

### Picture 4B:

Extension and flexion will be tested with a sizer in its place.

### Picture 5:

The radial collateral ligament is taken into holding suture and released from its metacarpal insertion, if needed. The final scaffold or sizer is used to evaluate the tightness and right reinsertion place of the collaterals. The scaffold is fixed to the metacarpal head with resorbable sutures (e.g. PDS, 2-0) passing through the metacarpal bone and via the distal palmar plate.

### Picture 6:

The final balancing of the joint is done by reinsertion of the ligaments into the trialed positions, often slightly at a more proximal and dorsal location, through drill holes in the proximal metacarpal bone.

The joint and soft tissues are closed in routine manner. Operated joints are supported with a palmar static splint for 10 days. The dynamic training orthosis is used for 2-3 months. Rehabilitation and physiotherapy is planned individually for each patient.

### Revisions:

In revision cases, old prosthesis as well as scar and granulation tissue are carefully removed from inside the metacarpal and phalangeal bones. Volar plates are released when necessary and intramedullary bone grafts are used. Otherwise the technique is similar to primary operations.

RegJoint™ is available in diameters 8-20mm. The correct size is always chosen individually; for this indication the most commonly used RegJoint™ diameters are 10-14 mm.

More detailed instructions can be found in RegJoint™ Instructions for use.

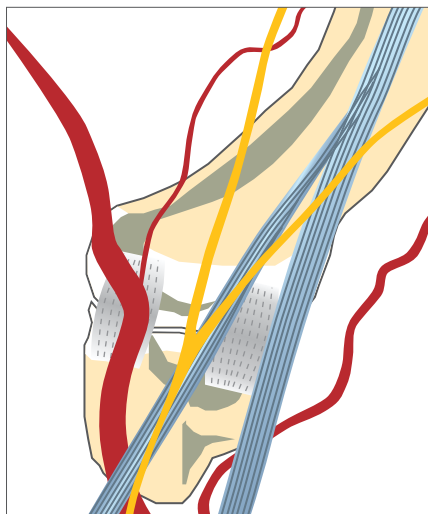


# RegJoint™

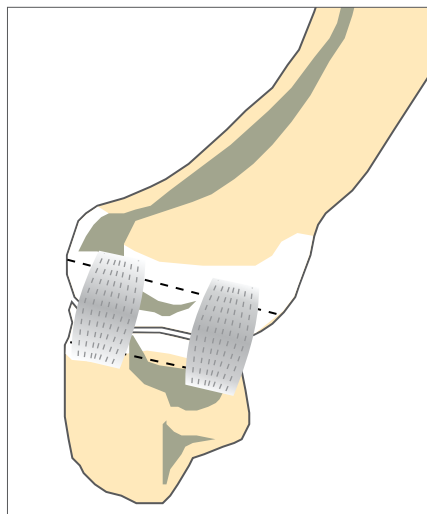
## surgical technique



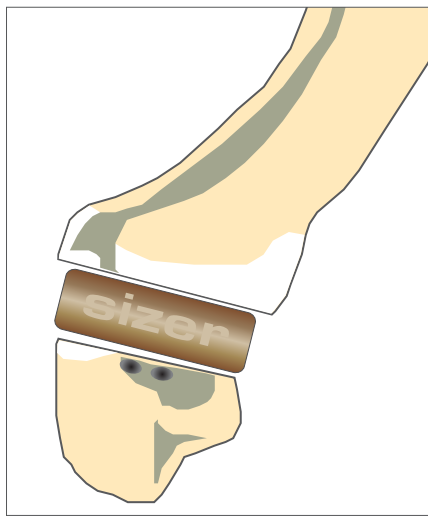Picture 1



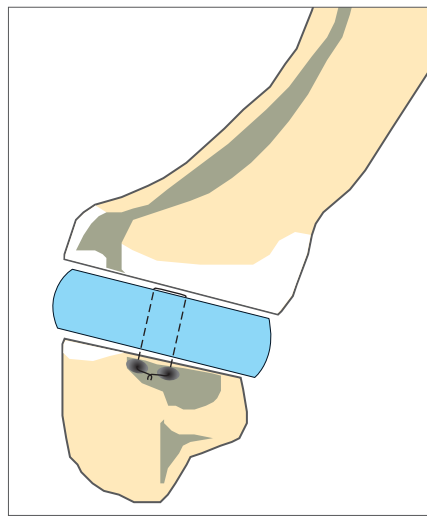
Picture 2



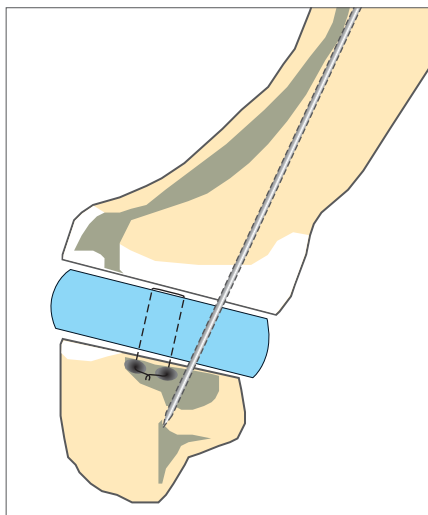
Picture 2



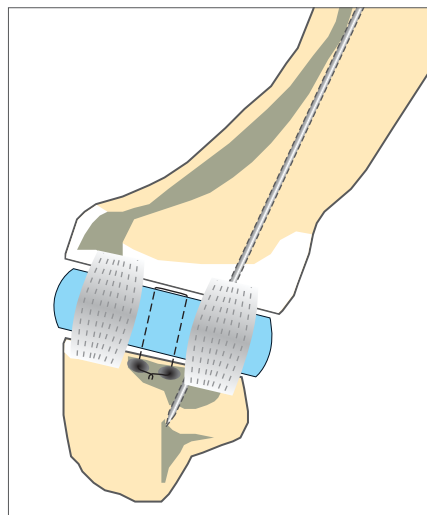
Picture 3



Picture 4



Picture 5



Picture 6

## The first carpometacarpal (CMC I) joint

### Picture 1:

Palmar or dorsal joint opening can be used.

### Picture 2:

The resection line of the proximal part of the first metacarpal is perpendicular with respect to the metacarpal. Resection of cartilage surface of the trapezium is performed using a curette or an oscillating saw. Other options are partial or complete trapezium resections without metacarpal resection. Extension of the resections is proportional to the joint laxity.

### Picture 3:

A RegJoint™ sizer can be used to evaluate the correct size of the implant.

### Picture 4:

The scaffold is fixed with transosseous resorbable sutures (e.g. PDS 2-0). Alternatively the scaffold can be fixed in into the joint capsule or with the surrounded flexor carpi radialis tendon.

### Picture 5:

The scaffold can also be fixed with a temporary K-wire going through the first metacarpal (or the whole thumb) to the resected joint line piercing the implant and trapezium up to the carpals. The supporting ligamentous sling can also be used as a stabilizer.

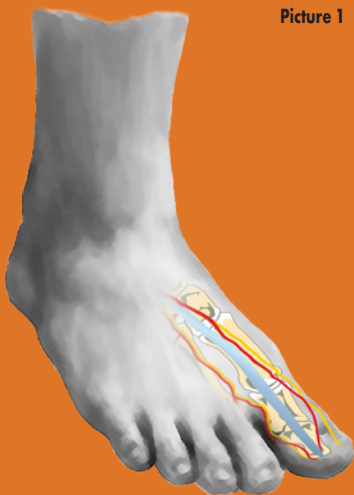### Picture 6:

A careful reconstruction of the joint capsule using absorbable suture material is performed.

Soft tissues and skin are closed in routine manner. Soft bandage is used. Rehabilitation and physiotherapy is planned individually for each patient.

RegJoint™ is available in diameters 8-20mm. The correct size is always chosen individually; for this indication the most commonly used RegJoint™ diameters are 12-16 mm.

More detailed instructions can be found in RegJoint™ Instructions for use.



# RegJoint™

## surgical technique

### Metatarsophalangeal (MTP I) joint

**Picture 1:**

Medial skin incision. Extra bunion is excised.

**Picture 2:**

Joint is opened in routine manner. Exostosis and osteophytes are excised and synovectomy performed, if needed.

**Picture 3:**

Metatarsal head resection.

**Picture 4:**

RegJoint™ sizer is used for evaluation of correct implant size. Ideal size completely covers the bone end. A scaffold is inserted on the metatarsal head.

**Picture 5 a:**

An external K-wire can be inserted from the tip of the big toe through the first MTP joint in the inside-out-in technique, fixating the implant and leading into the first metatarsal bone. Cut and bend or cover the K-wire and leave it external at the end of the toe.

**Picture 5 b:**

Alternatively, a scaffold can be sutured to the metatarsal head through bone canals with resorbable sutures (e.g. PDS 2-0) without K-wire. This technique is especially suitable in cases with minimal axis deviation.

**Picture 6:**

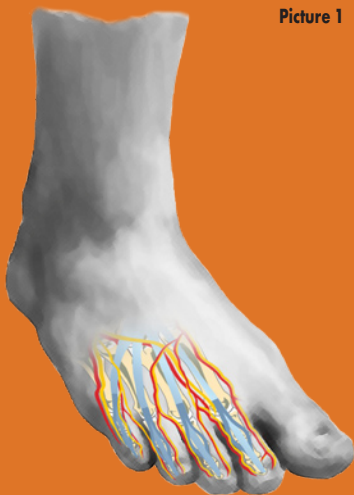
Medial joint capsule is closed tightly. Additional soft tissue release, if ideal position of the toe requires.

Subcutaneous tissue and skin are closed in routine manner. Tightening shall be avoided. Soft bandage is applied. External K-wire is drawn away after 2-4 weeks and a proper mobilization is encouraged in the 5th week. This applies to both fixation techniques. Support under the heel (leaving the resected metatarsal free) and the use of crutches are recommended during the first two weeks. Supporting footwear with firm sole is used for 4-6 weeks.

RegJoint™ is available in diameters 8-20mm. The correct size is always chosen individually; for this indication the most commonly used RegJoint™ diameters are 16-20 mm.

More detailed instructions can be found in RegJoint™ Instructions for use.





# RegJoint™

## surgical technique

### Metatarsophalangeal (MTP II-V) joints

**Picture 1:**

Transversal or two longitudinal skin incisions are performed.

**Picture 2:**

Joints are opened between extensor.

**Picture 3:**

Synovectomy is performed if needed, collateral ligaments are released and metatarsal heads resected.

**Picture 4:**

In case of a single metatarsal operation osteophytes are excised and the metatarsal head is remodelled. Plantar joint capsule is released from the metatarsal bone.

RegJoint™ sizer is used for evaluation of correct implant size. Ideal size completely covers the bone end. A scaffold is inserted on the metatarsal head.

**Picture 5 a:**

A scaffold can be sutured to the metatarsal head through bone canals with resorbable sutures (e.g. PDS 2-0).

**Picture 5 b:**

Alternatively, fixation with a K-wire from the tip of the toe to metatarsal bone via bone canals using the inside-out-in technique. K-wire is removed after 2-4 weeks.

**Picture 6:**

Extensor tendon adaptation with resorbable suture. If needed extensor brevis tendon can be cut off or extensor lengthening can be performed (commonly L-shaped).

Skin is closed in routine manner, tightening shall be avoided. Support under the heel (leaving the resected metatarsals free) and the use of crutches are recommended during the first two weeks. K-wire removal after 2-4 weeks. Supporting footwear with firm sole is used for 4-6 weeks, gradual mobilization of the toes after 4 weeks.

RegJoint™ is available in diameters 8-20mm. The correct size is always chosen individually; for this indication the most commonly used RegJoint™ diameters are 10-14 mm.

More detailed instructions can be found in RegJoint™ Instructions for use.

